

Case 122005-03: Two Year Reining Quarter Horse Colt Bilateral Subchondral Bone Cysts

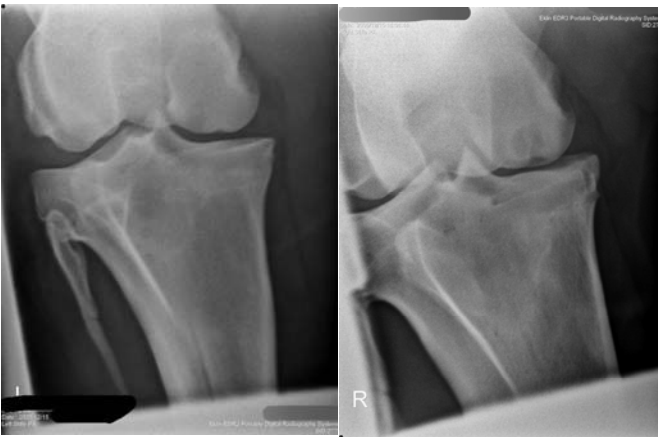
A two-year-old Quarter Horse was presented for lameness evaluation on April 15, 2005. On examination, the veterinarian noted that the patient stepped short on the left rear and was positive to high flexion test of same limb. A mild amount of joint effusion was palpated over the left femoral patellar joint. Fluoroscopy was performed on both stifles. Sclerosis and a cyst of the right medial femoral condyle were also noted. No treatments were administered at this time. The colt was prescribed calcium carbonate and a 30 day recheck was recommended.

Six months later, on December 15, 2005, a reevaluation was done: the patient was short on the right hind and positive to flexion test on both stifles. In order to more fully diagnose the etiology of the lameness of this Quarter horse, fluoroscopy of both stifles was performed and revealed sclerosis of both medial femoral condyles. Both stifles were injected with Hylartin and amikacin. At this time the veterinarian and the colt's owners elected to use regenerative cell therapy to treat the stifle joints.

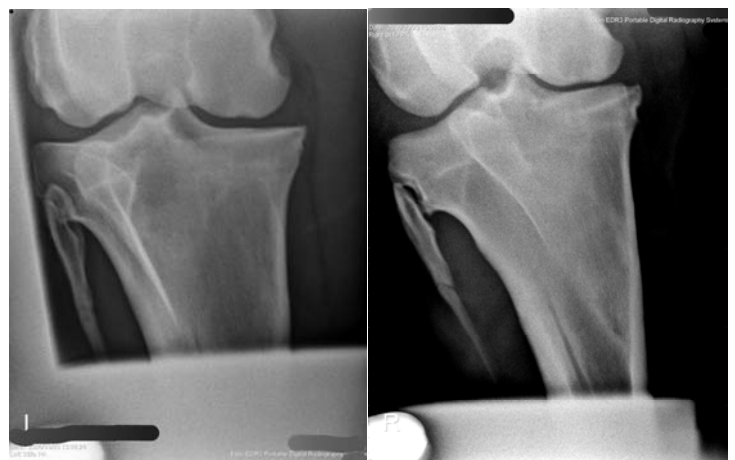
On December 20, 2005 a 22.49 gram sample of subcutaneous adipose tissue was taken and sent for collection of regenerative cells. On December 22, 2005 3.1 million regenerative cells were sterilely injected into each stifle joint. Post-injection, the patient was prescribed stall rest for 60 days.

On February 16, 2006, no lameness was detected while the colt was on longe line; he was also negative to flexion tests.

On reevaluation May 23, 2006, the colt still exhibited no lameness. Digital radiographs at this time showed marked density of the left rear medial femoral cyst. The right stifle also showed improvement as the density of the area of the medial femoral condyle had improved significantly on follow-up radiographs compared to the initial images.



Pre-Treatment, December 15, 2005



5 Months Post Treatment May 23, 2006

The Quarter Horse colt returned to full training and was entered in a futurity in Oklahoma city in November 2006.